

Resuscitative Endovascular Balloon Occlusion of the Aorta (REBOA) as an Option for Uncontrolled Hemorrhagic Shock: Current Best Practices and Anesthetic Implications

William Howie, DNP, CRNA

Michael Broussard, MS, CRNA

Bonjo Batoon, MS, CRNA

Noncompressible torso hemorrhage is reported to be a leading cause of potentially preventable mortality in both civilian trauma victims and military combat casualties. This hemorrhage may come from venous, arterial, or additional combined sources in the chest, abdomen, pelvis, axilla, or groin regions. Aortic occlusion as an adjunct to strategies for trauma damage control can decrease the amount of bleeding distal to the occluded site and provide a time-sensitive opportunity for resuscitation and definitive hemorrhage control. Recently, resuscitative endovascular balloon occlusion of the aorta (REBOA) has emerged as a temporary hemorrhage control and resuscitation technique that has the advantage of being minimally invasive and may offer improved patient morbidity and mortality

compared with the traditional emergency department thoracotomy. An overview of the history of REBOA and indications and contraindications for its use is provided. A placement strategy for this technology, which includes basic suggested insertion techniques and anatomical placement sites, is also provided. Additionally, device-related morbidity and mortality are addressed. Anesthetic implications in the perioperative period are reviewed in light of current best practices. Recommendations are given for future research aimed at refining and improving the care of seriously injured patients who may require this type of lifesaving treatment.

Keywords: Endovascular, hemorrhage, hemorrhage control, REBOA, trauma.

Major hemorrhage that originates in the torso presents a major treatment challenge, because there is no efficient and reliable method to control the bleeding without a surgical procedure and/or an interventional radiologic procedure.¹ Noncompressible torso injury (NCTI) and noncompressible torso hemorrhage (NCTH) have been reported to be leading causes of potentially preventable mortality in both civilian trauma and military combat casualties.^{2,3}

A recent analysis of the National Trauma Data Bank that included approximately 1.8 million patients found that there were 259,171 patients who met NCTI criteria. Patients who also had evidence of ongoing hemorrhage totaled 20,414 (8.2%). The most frequently noted types of injuries were attributable to pulmonary trauma (53%), followed by torso vascular injury (51%), solid organ damage (27%), and pelvic injury (9%). Major surgical exploration and repair were required in 68% of these patients, and 51% required intensive care unit (ICU) admission. The mortality rates for patients with NCTI and NCTH were calculated to be 6.8% and 44.6%, respectively. The single most lethal injury was major torso vascular trauma (odds ratio [OR] = 1.54, 95% confidence

interval [CI] = 1.33-1.77), followed by pulmonary injury (OR = 1.32, 95% CI = 1.18-1.48). The lowest mortality was reported in patients who suffered pelvic injury (OR = 0.80, 95% CI = 0.65-0.98).⁴

Noncompressible torso injury is a leading cause of preventable death following traumatic injury because a large number of victims with internal and external bleeding can exsanguinate before definitive treatment when providers are unable to apply direct pressure to an area of injury. This hemorrhage may come from venous, arterial, or additional combined sources in the chest, abdomen, pelvis, axilla, or groin regions.⁵ Aortic occlusion as an adjunct to strategies for trauma damage control can decrease the amount of bleeding distal to the occluded site, as well as provide a time-sensitive opportunity for resuscitation and definitive hemorrhage control.⁶ Options for aortic occlusion currently include direct clamping via an open surgical technique and resuscitative endovascular balloon occlusion of the artery (REBOA).⁷ Although surgeons and emergency department (ED) physicians with specialized training are typically responsible for performing REBOA, Certified Registered Nurse Anesthetists (CRNAs) are often called to provide anesthesia support and monitor such patients before, during, and following REBOA.

Attempts to control NCTH have historically included the use of an anterolateral ED thoracotomy, also called resuscitative thoracotomy, to facilitate aortic cross-clamping.⁸ The goal of this management strategy is to increase preload, temporarily control bleeding, and create an opportunity to provide internal cardiac massage and defibrillation, if indicated.⁹ The decision to perform an ED thoracotomy is typically reserved for patients with NCTH demonstrating profound hypotensive shock, those with near loss of vital signs, or patients who present pulseless with signs of life following penetrating thoracic injury.⁹ This technique is considered controversial because it is performed in a reactionary manner in response to profound patient cardiovascular collapse and exposes providers to bloodborne pathogens, potentially worsens blood loss, and contributes to coagulopathy by opening an otherwise intact and uninjured body cavity.^{9,10}

In recent years, REBOA has emerged as a temporary hemorrhage control and resuscitation technique that has the advantage of being minimally invasive, allows for preemptive placement of the balloon before full cardiovascular collapse, and may offer improved patient morbidity and mortality compared with ED thoracotomy.⁵ Additionally, minimally invasive endovascular techniques have been recommended as an effective internal hemorrhage control measure and for adequate support of vital organs, which offers better perfusion of vital organs during the damage control portion of exploratory surgery.¹¹ Many military and civilian healthcare providers have championed REBOA as a potentially effective method to decrease the amount of bleeding and provide valuable time to enable fluid resuscitation until definitive hemorrhage control is possible.¹

This article offers an overview of the history of REBOA, as well as indications and contraindications for its use. Following this discussion, an evidence-based clinical practice algorithm for placement of this technology is provided, including a basic overview of suggested device insertion techniques and anatomical placement sites. Additionally, device-related morbidity and mortality are addressed. Anesthetic implications in the perioperative period are reviewed in light of current best practice strategies. Finally, recommendations are given for future research aimed at refining and improving the care administered to seriously injured patients who may require this type of lifesaving treatment.

Historical Overview of REBOA

Historically, endovascular aortic occlusion using an intra-aortic balloon was first described by the US military to treat 2 injured soldiers during the Korean War.¹² Unfortunately, both soldiers died of their injuries, but the providers suggested there may have been a potential benefit in maintaining their vital signs while surgical repair was attempted.¹² During the 1980s, balloon occlusion was

attempted in a convenience sample of 23 patients with life-threatening hemorrhage.¹³ Of this group, 15 were trauma cases, 5 patients had ruptured abdominal aortic aneurysm (AAA), and 3 others had an undocumented injury of origin. Nine of 23 patients (39%) were noted to have vital signs when the balloon was inserted. All patients showed an increase in arterial blood pressure (BP) of about 50% to 100% ($P \leq .0001$). Two of 15 patients who sustained trauma (13%) and 4 patients with aneurysm in whom the balloon was used were long-term survivors. One individual lived for 2 weeks after 90 minutes of balloon aortic occlusion, before dying of ischemic complications. The investigators reported an overall survival rate of 26%. Eleven of 12 attempts to place the catheter by femoral cutdown were successful. However, just 7 of 12 attempts (58%) to place the catheter percutaneously were successful. The 6 insertion failures were reported to be due to too small an introducer, inability to identify arterial pulses in moribund patients, or difficulty in cannulating the femoral artery because of proximal occlusion.¹³

In another case study, intra-aortic balloon occlusion (IABO) of the thoracic aorta was attempted in 21 consecutive hemodynamically unstable patients with penetrating injuries of the abdomen.¹⁴ The patients were stratified into 3 groups. The first group was composed of 5 patients with a cardiac rhythm but no recordable BP. The second group contained 6 patients with refractory hypotension (systolic BP ≤ 80 mm Hg). The third group consisted of 10 patients who had hemodynamic deterioration, with a systolic BP of 80 mm Hg or less during preparation for or during surgical exploration. Intra-aortic balloon occlusion was successful in occluding the thoracic aorta in 20 patients (95%), with a resultant rise in BP; 1 patient required thoracotomy for aortic clamping. Operative control of hemorrhage was accomplished in 11 patients (52%); 7 patients survived (33%) and were discharged in a functional status. The only reported survivors were from the third group, those who had a systolic BP of 80 mm Hg or less during preparation for or during surgical exploration.¹⁴

Military engagement in the Middle East that commenced in 2003 stimulated additional interest in use of REBOA to reduce potentially preventable deaths due to NCTH.⁴ Specifically, autopsy results of soldiers who died of combat injuries in the Middle East determined that uncontrolled torso hemorrhage was the primary cause of preventable death in combat.¹⁵ More recent analysis of 4,596 combat fatalities indicated that uncontrolled hemorrhage accounted for 90% of potentially survivable casualties and that the most frequent site of lethal hemorrhage was truncal (67.3%).²

A systematic review of the literature on the use of REBOA in humans was conducted in 2016.¹⁶ The review determined that this procedure has been used in a variety of clinical situations, including postpartum

Indications	Contraindications
Hemorrhage control	Traumatic aortic injury
Ruptured aortic aneurysm	Hemorrhage proximal to zones of occlusion
Postpartum bleeding	
Hypotension from hemorrhagic shock	PEA > 10 minutes or terminal illness

Table. Indications and Contraindications for REBOA

Abbreviations: PEA, pulseless electrical activity; REBOA, resuscitative endovascular balloon occlusion of the artery.

hemorrhage, upper gastrointestinal tract bleeding, pelvic bleeding during sacral/pelvic tumor surgery, traumatic abdominopelvic bleeding, and bleeding from a ruptured AAA. Following deployment of the balloon, systolic BP increased by a mean value of 53 mm Hg. The mortality rate among patients in this pooled study ranged from 8% to 86% when REBOA was used in traumatically injured patients and those who sustained a ruptured AAA.

Perhaps the largest reported use of REBOA as part of damage control surgery and resuscitation originated in Japan. Of 45 patients who were treated with REBOA, there were 26 survivors (57.8%). The researchers found that REBOA was used to facilitate other clinical interventions, including angioembolization,¹⁷ resuscitative thoracotomy,⁶ and abdominal surgery.¹⁸ There was a positive statistically significant difference between survivors and nonsurvivors in terms of injury severity and total occlusion time. That is, survival rates were lower in those with more severe injury and in those with longer total occlusion time (224 ± 52 minutes vs 46 ± 15 minutes, $P = .002$).¹⁸

A contemporary case series of 4 patients with combat-related torso gunshot or fragmentation wounds, hemoperitoneum, and class 4 shock highlighted the importance of REBOA as part of a damage control strategy.¹⁹ The authors reported that REBOA performed in an austere environment, in conjunction with whole blood transfusion, permitted completion of a damage control laparotomy and surgical hemostasis. All patients were then transferred to the next level of care in stable condition. The length of balloon inflation time ranged from 18 to 65 minutes, and no access-related or catheter-related complications were reported. Handheld ultrasonography was used to diagnose hemoperitoneum and to facilitate 7F femoral sheath access. The ER-REBOA balloons were positioned and inflated in the aorta (zone 1 [n = 3] and zone 3 [n = 1]) without radiography.

Review of the literature demonstrates that the survival of patients with severe NCTI and NCTH depends greatly on a knowledgeable and multidisciplinary team that includes prehospital providers, trauma surgeons, trauma anesthesia providers, and trained operating room nurses and technicians. Also critical for survival are a fully stocked and staffed operating room, efficient laboratory and blood bank services, and potentially the availability of an interventional radiology (IR) suite.²⁰

Indications and Contraindications for REBOA

As described, the primary indication for use of REBOA is temporary hemorrhage control. As noted previously, uncontrolled hemorrhagic shock is a significant contributor to mortality.²⁰ Surgical laparotomy or IR methods remain the definitive treatment measures for hemorrhage control.²¹ Deployment of operative or IR team members can be a time-consuming process. The mobilization of surgical, anesthesia, and nursing care providers, along with transfer of the patient to the operating room or IR suite, can delay definitive treatment. Placement of the REBOA device in the ED may provide the vital time that is needed before definitive repair.

The REBOA device is considered a less invasive method of hemorrhage control compared with open resuscitative thoracotomy for aortic cross-clamp.²¹ It may be indicated for hemorrhage caused by blunt or penetrating trauma, ruptured aortic aneurysm, and postpartum bleeding from placenta previa or placental abruption. Relative indications include selected adult patients aged 18 to 69 years, systolic BP below 70 mm Hg due to hemorrhagic shock, pulseless electrical activity arrest of less than 10 minutes' duration caused by hemorrhage, and hemorrhagic shock caused by noncompressive bleeding.¹⁶

The contraindications associated with the use of REBOA include the presence of a traumatic aortic injury and hemorrhage proximal to the zones of occlusion, including areas of the neck, axilla, and superior mediastinum.^{7,8} Suspected aortic injuries can be diagnosed using chest radiography and should preclude use of REBOA. Relative contraindications include elderly age (age > 70 years), pulseless electrical activity arrest longer than 10 minutes, presence of terminal illness, or profound comorbidities (Table).¹⁶

Placement of REBOA Device

Once the decision has been made by the surgeon or ED physician to perform REBOA, the 5-step process for the REBOA procedure includes arterial access, balloon selection and positioning, balloon inflation, balloon deflation, and sheath removal (Figure).²²

The initial step is to cannulate the common femoral artery. According to the Aortic Occlusion for Resuscitation in Trauma and Acute Care Surgery (AORTA) registry, femoral arterial access for REBOA is usually accomplished using femoral cutdown (50%), percutaneously

without imaging (28.3%), and with ultrasonography guidance (10.9%).²³ The use of ultrasonography has several advantages over the landmark-based techniques, which include the rapid identification of pertinent anatomical structures, decreased complication and failure rates, and fewer total number of attempts for successful cannulation.²⁴ Importantly, surgical cutdown to access the femoral vessels should be performed by those with appropriate training for such procedures.

After the common femoral artery is accessed, the guidewire is placed, and the introducer sheath is slid over the guidewire and into the artery. Traditionally, large sheaths (up to 14F) were required to accommodate the Coda balloon catheter (Cook Medical) for REBOA, but the ER-REBOA catheter (Prytime Medical), recently approved by the U.S. Food and Drug Administration, allows easier placement via a 7F sheath.⁵ Once the REBOA introducer is in place, the landing zone should be determined via external landmarks, chest radiography, or fluoroscopy. Placement in zone 1 (origin of the left subclavian artery to the celiac arteries) is considered for positive focused assessment with sonography in trauma (FAST) for treatment of suspected intra-abdominal hemorrhage, whereas zone 3 (from the lowest renal artery to the aortic bifurcation) placement is for treatment of suspected pelvic hemorrhage; zone 2 is considered a no landing zone for REBOA.²²

With measurements taken and placement zone determined, the REBOA catheter is placed through the introducer to the desired depth, and placement is confirmed by radiography or fluoroscopy, if available. The Coda balloon is inserted over the wire, but the ER-REBOA balloon is inserted directly through the introducer sheath, and the balloon is inflated with a combination of saline and contrast medium until moderate resistance occurs. The amount of fluid instilled should be documented, and the same amount of solution will need to be withdrawn at the time of balloon deflation. The physiologic response to balloon inflation should be continuously monitored and communicated with the surgical team. A case series that involved 6 patients demonstrated a mean increase in systolic BP of 55 mm Hg with inflation of the REBOA balloon and a mean aortic occlusion (AO) time of 18 minutes.²⁵ Although no consensus exists, balloon inflation time should be kept to a minimum to decrease the physiologic insult associated with prolonged aortic occlusion.

It is important to note that if an existing femoral arterial line is used as the entry point for the REBOA, monitoring of BP from that site will be lost. Blood pressures should be measured noninvasively until arterial access above the diaphragm (radial, brachial or axillary) is established or until intra-aortic monitoring can occur from the tip of the ER-REBOA. Older REBOA catheters such as the Coda balloon catheter lack this ability.

During AO, expedient surgical exploration should occur

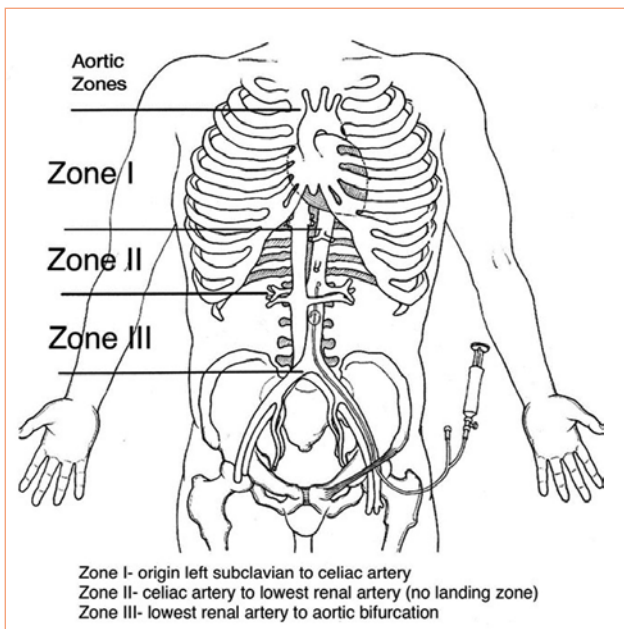


Figure. Anatomical Zones for REBOA Device Placement
Abbreviation: REBOA, resuscitative endovascular balloon occlusion of the artery.

to identify and treat life-threatening injuries. Resuscitation should be ongoing, with appropriate administration of blood and blood products. Once surgical control of life-threatening injuries has occurred, plans should be made for deflation of the REBOA balloon. Communication among surgical and anesthesia staff is imperative.

Partial REBOA is a modification that preserves organ perfusion above occlusion but allows for hypotension resuscitation below the level of AO. This technique may decrease ischemia and reperfusion injuries associated with AO.²⁶ Additionally, hypotensive resuscitation below the level of the balloon may allow for identification and control of hemorrhage distal to the REBOA.²⁴

Deflation of the REBOA balloon should occur in a slow and controlled fashion with continuous monitoring of physiologic response to deflation. Also during this time, blood products and vasoactive medications should be available for immediate administration during the deflation process. Once the patient has been stabilized and the REBOA device is no longer needed, patients receiving REBOA with the Coda catheter must return to the operating room to have the introducer sheath removed and the artery repaired under direct visualization.²² This step can be eliminated if the ER-REBOA device is used because of the small diameter of the introducer. In such cases, direct pressure may be used after removal of the sheath.⁵

Related Morbidity and Mortality

Most complications of REBOA are attributable to IABO and sheath insertion. The IABO catheter may cause vessel injuries, which can include aortic dissection, aortic rupture, and aortic perforation.²⁷ Other complications

from IABO include air emboli, peripheral ischemia, and embolization.²⁷ To diminish the risk of complications, practitioners often use ultrasonography or fluoroscopy to guide the position of the IABO catheter. Guliani et al²⁸ reported that ultrasonography alone is a safe and accurate method for positioning and deployment of the IABO catheter compared with fluoroscopy.

The primary complications of sheath insertion are related to femoral artery injuries.²⁹ They include femoral artery dissection, pseudoaneurysm, and arteriovenous fistula formation. Another complication of sheath insertion is ischemia distal to the sheath placement.¹ A retrospective evaluation of REBOA safety by Saito et al⁵ showed lower limb ischemia on the side of sheath insertion. In some cases, the ischemia was severe enough to require limb amputation. Other risk factors for vascular injury include sex (female greater than male), high body mass index, larger sheath size, low platelet count, and advanced age.

Anesthetic Implications for REBOA

The care of a patient in hemorrhagic shock who requires REBOA presents many challenges. It is critical to adhere to current principles of damage control resuscitation and to use a readily available multidisciplinary team of nurses, technicians, anesthesia providers, and physicians who are knowledgeable about the management of such patients. Initial management includes conducting a focused primary survey of injuries, as well as use of rapid imaging modalities to assess for signs of internal (noncompressible) injuries and bleeding (focused ultrasonography and radiographs of the chest, abdomen, and pelvis); initiation of a massive transfusion event; securing a definitive airway; and placement of large-bore peripheral and central vascular access devices as necessary, and arterial access devices. It is reasonable to consider insertion of a femoral arterial line in a patient with suspected NCTH to serve as a monitor of beat-to-beat BP. Additionally, providers will want to quickly determine a potential site to place a REBOA device should one become necessary in the early stages of patient evaluation and resuscitation.²⁰

Damage control resuscitation (DCR) combines damage control surgery with body rewarming, restriction of crystalloid fluid administration, permissive hypotension, and balanced use of blood products (1:1:1 ratio of packed red blood cells, fresh frozen plasma, and platelets). Utilization of a massive transfusion event with administration of tranexamic acid should be considered within 3 hours of injury, if possible.³⁰⁻³⁶ Additionally, pharmacologic interventions may be required to correct hyperkalemia, hypocalcemia, acidosis, hemodynamic instability during resuscitation, and eventual reperfusion after REBOA deflation. The most recent management guidelines endorsed by the Eastern Association for the

Surgery of Trauma and the European guidelines concerning the management of a patient with severe traumatic hemorrhage include the use of DCR and massive transfusion event, both of which are thought to significantly improve clinical outcomes.³⁶

Placement of the REBOA device is designed to help maintain cerebral and coronary circulation by temporarily limiting arterial bleeding from the injured organ when the aortic lumen is occluded by the balloon.³⁷ It is critical to remember that REBOA is a temporary attempt to control hemorrhage while some form of surgical correction is obtained, because prolonged inflation times have been associated with increased mortality.¹⁹ Although not clearly demonstrated in human trials, several animal experiments have found that limiting occlusion time to no longer than 60 minutes helps to mitigate accumulation of lactate and interleukin-6, both of which can lead to a significant systemic inflammatory response in the patient once the balloon is deflated.³⁸ A potential strategy to minimize this response has been performed with success in an animal model by partial REBOA throughout the study period.³⁹ Additionally, a periodic release of the balloon during the DCS procedure, either to identify a bleeding focus or to permit transient reperfusion, between occlusion periods has been reported as beneficial.⁵ Hemodynamic management and oxygenation of the patient during the period of AO should attempt to maximize overall patient perfusion and should be guided using standard laboratory tests, including arterial blood gas analysis; measurement of lactate and hemoglobin levels; platelet count; and viscoelastic monitoring to help guide hemostatic resuscitation.⁵

In an attempt to standardize clinical end points for correcting coagulopathy, a consensus statement of the College of American Pathologists, American Society of Anesthesiologists, and European Guidelines by the Task Force for Advanced Bleeding Care in Trauma recommends administering procoagulant products to maintain an international normalized ratio (INR) of less than 1.5 and a platelet count greater than $50,000 \times 10^3/\mu\text{L}$.⁴⁰ In cases in which a coagulopathy is suspected, viscoelastic assays (eg, TEG [Haemonetics], ROTEM [Tem International]) as well as a platelet count are recommended. In the event that the viscoelastic assays are not available, standard coagulation tests are obtained (eg, INR, activated partial thromboplastin time, fibrinogen concentration, platelet count).⁴⁰ It is critical that communication with the surgeon be maintained throughout all phases of DCS, and any decision to inflate or deflate the balloon should be discussed to help ensure optimal fluid and perfusion parameters.⁵ When the aorta is occluded with a balloon, there is a resultant increase in cardiac afterload raising mean arterial pressure, thereby causing shifts in blood volume and increasing myocardial oxygen demand. Such conditions can lead to left ventricular de-

compensation and failure.⁴¹ In addition, there is ischemia induced on portions of the body distal to the occlusion, which is similar to that which may be seen during open aortic surgery with a cross-clamp.⁴¹ Once the clamp is released, there is a triggered ischemia-reperfusion response that may produce multiple pathophysiologic processes, such as systemic inflammation, humeral changes, and metabolite circulation that can lead to multiple system organ injury.⁴¹ At times, it may be necessary to deflate the balloon partially, either to identify areas of active bleeding or to permit transient reperfusion between occlusion periods. Any decisions by the surgeons to deflate the balloon must be made in concert with the anesthesia team, so that efforts may be taken to volume resuscitate the patient and add vasoactive medications as necessary, to avoid a precipitous cardiovascular collapse following balloon deflation. Once the balloon is fully deflated, it is prudent to leave the catheter in place until the surgical or endovascular maneuvers are completed in case emergent reinflation becomes necessary.⁵

Typically, the patient will be transported from the operating room to an ICU for continued resuscitation and correction of hypothermia, acid base, lactate, and coagulation disorders, which may be a part of the DCR process.⁴² It is also possible that the patient will be taken to an IR suite for potential endovascular control of any ongoing internal bleeding.⁴³ Available literature supports the use of hybrid operative suites as a more efficient way to quickly treat NCTH.⁴⁴ Thus, it may be necessary for the anesthesia provider to provide general anesthesia and continue resuscitative efforts during the IR endovascular repair and during an open surgical exploration.

Conclusion

The future of acute trauma care may include the proactive use of REBOA in the prehospital environment to limit active hemorrhage in select patients with NCTH to permit improved outcomes in severely injured trauma patients.^{45,46} Looking forward, it is likely that specially trained nonphysician providers may be called on to perform REBOA, particularly in austere environments. In addition, the use of hybrid angiography operating rooms that allow a patient to stay in the same location for IR and open repair, as needed, is being developed. This concept has been termed RAPTOR, an acronym for resuscitation with angiography, percutaneous techniques, and operative repair.^{47,48} Taken in the context of damage control, this minimally invasive technique, 3 specific interventional procedures to control bleeding include temporary balloon arterial occlusion, embolization to occlude arteries, and stent grafting to repair injured vessels.⁴³ The use of REBOA as an adjunct to both DRS and DCR efforts is becoming more common in the acute management of patients with hemorrhagic shock.^{35,49}

REFERENCES

1. Qasim Z, Brenner M, Menaker J, Scalea T. Resuscitative endovascular balloon occlusion of the aorta. *Resuscitation*. 2015;96:275-279.
2. Eastridge BJ, Mabry RL, Seguin P, et al. Death on the battlefield (2001-2011): implications for the future of combat casualty care. *J Trauma Acute Care Surg*. 2012;73(6 suppl 5):S431-S437.
3. Morrison JJ, Stannard A, Rasmussen TE, Jansen JO, Tai NR, Midwinter MJ. Injury pattern and mortality of noncompressible torso hemorrhage in UK combat casualties. *J Trauma Acute Care Surg*. 2013;75(2 suppl 2):S263-S268.
4. Kisat M, Morrison JJ, Hashmi ZG, Efron DT, Rasmussen TE, Haider AH. Epidemiology and outcomes of non-compressible torso hemorrhage. *J Surg Res*. 2013;184(1):414-421.
5. Saito N, Matsumoto H, Yagi T, et al. Evaluation of the safety and feasibility of resuscitative endovascular balloon occlusion of the aorta. *J Trauma Acute Care Surg*. 2015;78(5):897-903.
6. Morrison JJ, Rasmussen TE. Noncompressible torso hemorrhage: a review with contemporary definitions and management strategies. *Surg Clin North Am*. 2012;92(4):843-858. vii.
7. Rasmussen TE, Cannon JE. Endovascular methods for aortic control in trauma. UpToDate website. <https://www.uptodate.com/contents/endovascular-methods-for-aortic-control-in-trauma>. Accessed January 8, 2018. Updated November 7, 2018.
8. Moore LJ, Brenner M, Kozar RA, et al. Implementation of resuscitative endovascular balloon occlusion of the aorta as an alternative to resuscitative thoracotomy for noncompressible truncal hemorrhage. *J Trauma Acute Care Surg*. 2015;79(4):523-530.
9. van Oostendorp SE, Tan EC, Geeraedts LM Jr. Prehospital control of life-threatening truncal and junctional haemorrhage is the ultimate challenge in optimizing trauma care; a review of treatment options and their applicability in the civilian trauma setting. *Scand J Trauma Resusc Emerg Med*. 2016;24(1):110.
10. Seamon MJ, Haut ER, Van Arendonk K, et al. An evidence-based approach to patient selection for emergency department thoracotomy: a practice management guideline from the Eastern Association for the Surgery of Trauma. *J Trauma Acute Care Surg*. 2015;79(1):159-173.
11. Moore LJ, Martin CD, Harvin JA, Wade CE, Holcomb JB. Resuscitative endovascular balloon occlusion of the aorta for control of non-compressible truncal hemorrhage in the abdomen and pelvis. *Am J Surg*. 2016;212(6):1222-1230.
12. Kleber C, Giesecke MT, Tsokos M, Haas NP, Buschmann CT. Trauma-related preventable deaths in Berlin 2010: need to change prehospital management strategies and trauma management education. *World J Surg*. 2013;37(5):1154-1161.
13. Hughes CW. Use of an intra-aortic balloon catheter tamponade for controlling intra-abdominal hemorrhage in man. *Surgery*. 1954;36(1):65-68.
14. Low RB, Longmore W, Rubinstein R, Flores L, Wolvek S. Preliminary report on the use of the Percluter occluding aortic balloon in human beings. *Ann Emerg Med*. 1986;15(12):1466-1469.
15. Gupta BK, Khaneja SC, Flores L, Eastlick L, Longmore W, Shaftan GW. The role of intra-aortic balloon occlusion in penetrating abdominal trauma. *J Trauma*. 1989;29(6):861-865.
16. Holcomb JB, McMullin NR, Pearse L, et al. Causes of death in U.S. Special Operations Forces in the global war on terrorism: 2001-2004. *Ann Surg*. 2007;245(6):986-991.
17. Morrison JJ, Galgon RE, Jansen JO, Cannon JW, Rasmussen TE, Eliason JL. A systematic review of the use of resuscitative endovascular balloon occlusion of the aorta in the management of hemorrhagic shock. *J Trauma Acute Care Surg*. 2016;80(2):324-334.
18. Ogura T, Lefor AT, Nakano M, Izawa Y, Morita H. Nonoperative management of hemodynamically unstable abdominal trauma patients with angioembolization and resuscitative endovascular balloon occlusion of the aorta. *J Trauma Acute Care Surg*. 2015;78(1):132-135.
19. Irahara T, Sato N, Moroe Y, Fukuda R, Iwai Y, Unemoto K. Retrospective study of the effectiveness of intra-aortic balloon occlusion (IABO) for traumatic haemorrhagic shock. *World J Emerg Surg*. 2015;10(1):1.
20. Manley JD, Mitchell BJ, Dubose JJ, Rasmussen TE. A modern case series of resuscitative endovascular balloon occlusion of the aorta

- (REBOA) in an out-of-hospital, combat casualty care setting. *J Spec Oper Med*. 2017;17(1):1-8.
21. Brenner M, Rasmussen TE. A team approach to endovascular management of hemorrhagic shock. *Endovascular Today*. 2017;16(1):57-60.
 22. Stannard A, Eliason JL, Rasmussen TE. Resuscitative endovascular balloon occlusion of the aorta (REBOA) as an adjunct for hemorrhagic shock. *J Trauma*. 2011;71(6):1869-1872.
 23. Dubose JJ, Scalea TM, Brenner M, et al; AAST AORTA Study Group. The AAST prospective Aortic Occlusion for Resuscitation in Trauma and Acute Care Surgery (AORTA) registry: data on contemporary utilization and outcomes of aortic occlusion and resuscitative balloon occlusion of the aorta (REBOA). *J Trauma Acute Care Surg*. 2016;81(3):409-419.
 24. Dubose JJ. How I do it: partial resuscitative endovascular balloon occlusion of the aorta (P-REBOA). *J Trauma Acute Care Surg*. 2017;83(1):197-199.
 25. Brenner ML, Moore LJ, Dubose JJ, et al. A clinical series of resuscitative endovascular balloon occlusion of the aorta for hemorrhage control and resuscitation. *J Trauma Acute Care Surg*. 2013;75(3):506-511.
 26. Johnson MA, Neff LP, Williams TK, Dubose JJ; EVAC Study Group. Partial resuscitative balloon occlusion of the aorta (P-REBOA): clinical technique and rationale. *J Trauma Acute Care Surg*. 2016;81(5 suppl 2 Proceedings of the 2015 Military Health System Research Symposium):S133-S137.
 27. Stone PA, Campbell JE, AbuRahma AF. Femoral pseudoaneurysms after percutaneous access. *J Vasc Surg*. 2014;60(5):1359-1366.
 28. Guliani S, Amendola M, Strife B, et al. Central aortic wire confirmation for emergent endovascular procedures: as fast as surgeon-performed ultrasound. *J Trauma Acute Care Surg*. 2015;79(4):549-554.
 29. Brenner M, Hoehn M, Teeter W, Stein D, Scalea T. Resuscitative endovascular balloon occlusion of the aorta: a gap analysis of severely injured UK combat casualties. *J Trauma Acute Care Surg*. 2016;41:783-786.
 30. Lamb CM, MacGoey P, Navarro AP, Brooks AJ. Damage control surgery in the era of damage control resuscitation. *Br J Anaesth*. 2014;113(2):242-249.
 31. Holcomb JB, Tilley BC, Baraniuk S, et al; PROPPR Study Group. Transfusion of plasma, platelets, and red blood cells in a 1:1:1 vs. 1:1:2 ratio and mortality in patients with severe trauma: the PROPPR randomized clinical trial. *JAMA*. 2015;313(5):471-482.
 32. Ball CG. Damage control resuscitation: history, theory and technique. *Can J Surg*. 2014;57(1):55-60.
 33. Binz S, McColester J, Thomas S, et al. CRASH-2 study of tranexamic acid to treat bleeding in trauma patients: a controversy fueled by science and social media. *J Blood Transfus*. 2015;2015:874920.
 34. Rossaint R, Bouillon B, Cerny V, et al. The European guideline on management of major bleeding and coagulopathy following trauma: fourth edition. *Crit Care*. 2016;20:100.
 35. Giannoudi M, Harwood P. Damage control resuscitation: lessons learned. *Eur J Trauma Emerg Surg*. 2016;42(3):273-282.
 36. Cannon JW, Khan MA, Raja AS, et al. Damage control resuscitation in patients with severe traumatic hemorrhage: a practice management guideline from the Eastern Association for the Surgery of Trauma. *J Trauma Acute Care Surg*. 2017;82(3):605-617.
 37. Tsurukiri J, Akamine I, Sato T, et al. Erratum to: Resuscitative endovascular balloon occlusion of the aorta for uncontrolled haemorrhagic [sic] shock as an adjunct to haemostatic procedures in the acute care setting. *Scand J Trauma Resusc Emerg Med*. 2016;24:72.
 38. Morrison JJ, Ross JD, Markov NP, Scott DJ, Spencer JR, Rasmussen TE. The inflammatory sequelae of aortic balloon occlusion in hemorrhagic shock. *J Surg Res*. 2014;191(2):423-431.
 39. Russo RM, Neff LP, Lamb CM, et al. Partial resuscitative endovascular balloon occlusion of the aorta in swine model of hemorrhagic shock. *J Am Coll Surg*. 2016;223(2):359-368.
 40. American Society of Anesthesiologists Task Force on Perioperative Blood Management. Practice guidelines for perioperative blood management: an updated report by the American Society of Anesthesiologists Task Force on Perioperative Blood Management. *Anesthesiology*. 2015;122(2):241-275.
 41. Zammert M, Gelman S. The pathophysiology of aortic cross-clamping. *Best Pract Res Clin Anaesthesiol*. 2016;30(3):257-269.
 42. Grabo D, Strumwasser A. Maintaining the critical care continuum in resuscitation. *Int Anesthesiol Clin*. 2017;55(3):130-146.
 43. Chakraverty S, Zealley I, Kessel D. Damage control radiology in the severely injured patient: what the anaesthetist needs to know. *Br J Anaesth*. 2014;113(2):250-257.
 44. Tesoriero RB, Bruns BR, Narayan M, et al. Angiographic embolization for hemorrhage following pelvic fracture: Is it "time" for a paradigm shift? *J Trauma Acute Care Surg*. 2017;82(1):18-26.
 45. Valkenburg A, Bennett D, Bishop J, Smith G. Resuscitative endovascular balloon occlusion of the aorta as a potential pre-hospital procedure for the control of non-compressible haemorrhage: a literature review. *Aust J Paramed*. 2015;12(4):1-8. <https://ajp.paramedics.org/index.php/ajp/article/view/146/512>. Accessed January 8, 2018.
 46. Sadek S, Lockey DJ, Lendrum RA, Perkins Z, Price J, Davies GE. Resuscitative endovascular balloon occlusion of the aorta (REBOA) in the pre-hospital setting: an additional resuscitation option for uncontrolled catastrophic haemorrhage. *Resuscitation*. 2016;107:135-8.
 47. Ball CG, Kirkpatrick AW, D'Amours SK. The RAPTOR: Resuscitation with angiography, percutaneous techniques and operative repair. Transforming the discipline of trauma surgery. *Can J Surg*. 2011;54(5):E3-E4.
 48. Kirkpatrick AW, Vis C, Dubé M, et al. The evolution of a purpose designed hybrid trauma operating room from the trauma service perspective: the RAPTOR (Resuscitation with Angiography Percutaneous Treatments and Operative Resuscitations). *Injury*. 2014;45(9):1413-1421.
 49. Bunya N, Harada K, Kuroda Y, et al. The effectiveness of hybrid treatment for severe [sic] multiple trauma: a case of multiple trauma for damage control laparotomy and thoracic endovascular repair. *Int J Emerg Med*. 2017;10(1):18.

AUTHORS

William Howie, DNP, CRNA, is a staff nurse anesthetist at the University of Maryland R. Adams Cowley Shock Trauma Center in Baltimore, Maryland. Email: bhowie@som.umaryland.edu.

Michael Broussard, MS, CRNA, is a staff nurse anesthetist at the University of Maryland R. Adams Cowley Shock Trauma Center. Email: mbroussard@som.umaryland.edu.

Bonjo Batoon, MS, CRNA, is a staff nurse anesthetist at the University of Maryland R. Adams Cowley Shock Trauma Center. Email: bbatoon@som.umaryland.edu.

DISCLOSURES

The authors have declared no financial relationships with any commercial entity related to the content of this article. The authors did not discuss off-label use within the article.